

MASTERKA is a pushed lacrimal intubation stent with self-retaining meatic fixation. The metallic guide is located inside the lumen, **not as an extension of the stent as in conventional stents.**

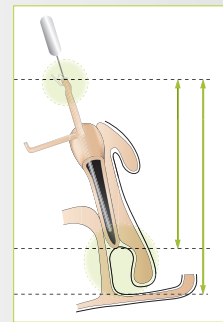
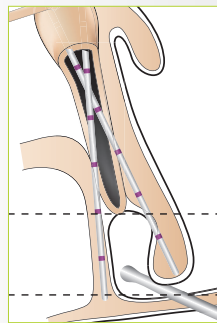
MASTERKA is available in three lengths: 30, 35 and 40 mm.

Individually packaged, sterile
 S1.1608 **Masterka 30 mm**
 S1.1609 **Masterka 35 mm**
 S1.1610 **Masterka 40 mm**
 S1.1289 **Sizer**

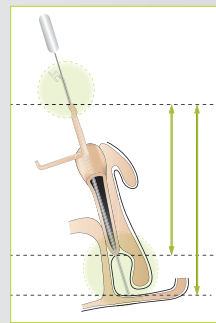


SPECIAL CASES

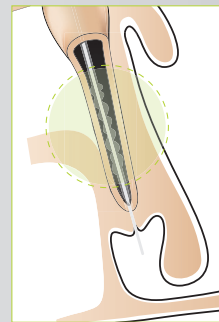
▼ False passage



▼ Stent too long



▲ Stent too short



▲ Complex nasolacrimal stenosis




For more information please contact your local distributor:



MASTERKA®

SELF-RETAINING
 MONOCANALICULAR
NASAL INTUBATION
 WITHOUT
 NASAL RECOVERY

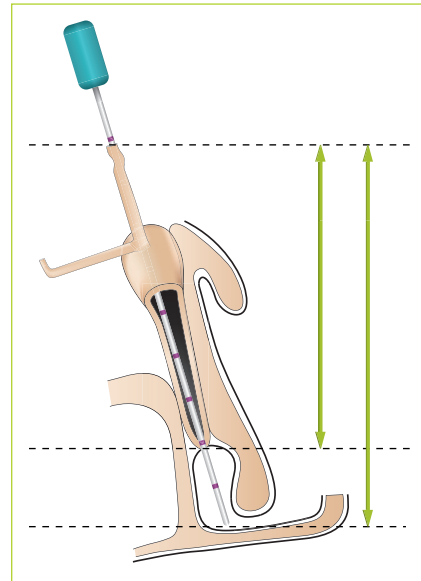


FCI 11/013.ind B - 06/2014 - Creation and drawing: **agisson** : 01 53 80 00 66 - crédits photos Dr. B. Fayet
 Laboratoire Graphique

INDICATIONS

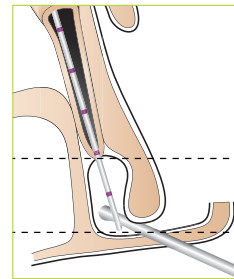
- Simple nasolacrimal duct obstructions in children, particularly resistant to probing.
- Monocanalicular agenesis.

INITIAL PROBING



▲ Sizer in place

Metal-to-metal contact ▶



Diagnosis:

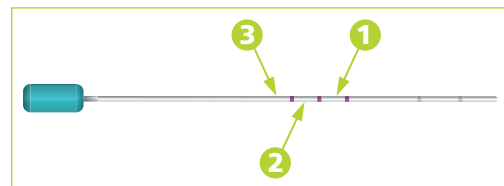
Complex stenosis (contra-indication) is distinguished from scarred nasolacrimal stenosis by tactile probing.

Detecting false passages:

A second, wider lacrimal stent with a blunt tip is inserted and very gently steered through the inferior nasal meatus, until metal-to-metal contact is achieved.

Selection of stent length:

When the exploratory probe ref. S1.1289 contacts the nasal fossa floor, note the location of the punctal opening on the measuring device:



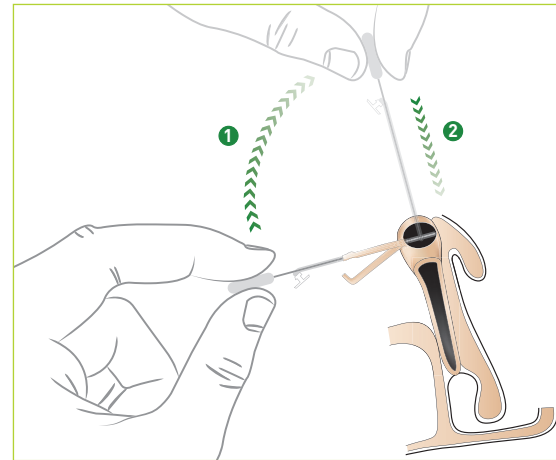
Position 1: Use Masterka® 30 mm

Position 2: Use Masterka® 35 mm

Position 3: Use Masterka® 40 mm

Generally speaking, the stent should be approximately 5 mm longer than the distance between the punctum and the nasolacrimal stenosis. **It does not need to be longer than the distance between the punctum and the nasal fossa floor.**

NASO-MONOCANALICULAR INTUBATION

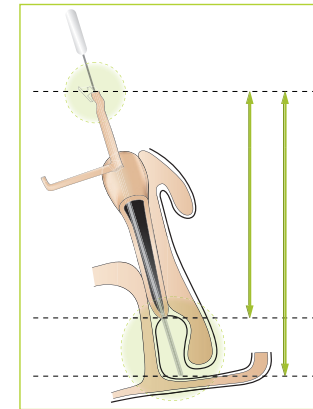


▲ Intubation

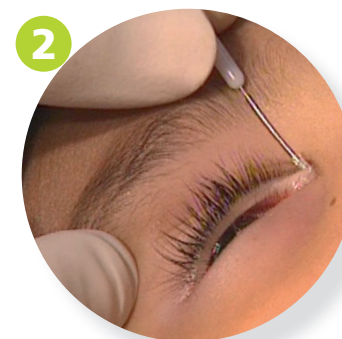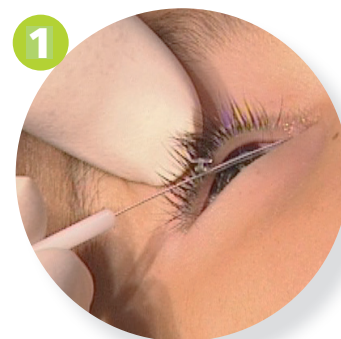The punctum is dilated.

Search for bony contact.

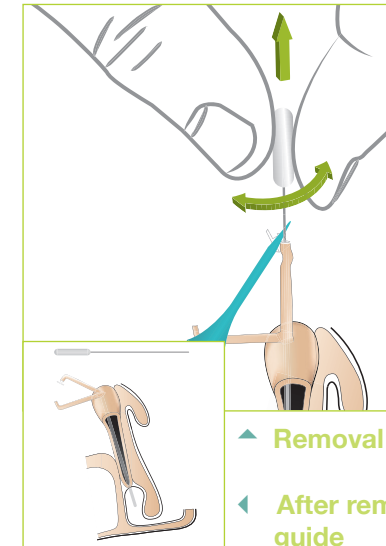
Vertical catheterization: Push until the plug comes in contact with the punctum.



▲ Stent in place



REMOVING THE METALLIC GUIDE



▲ Removal

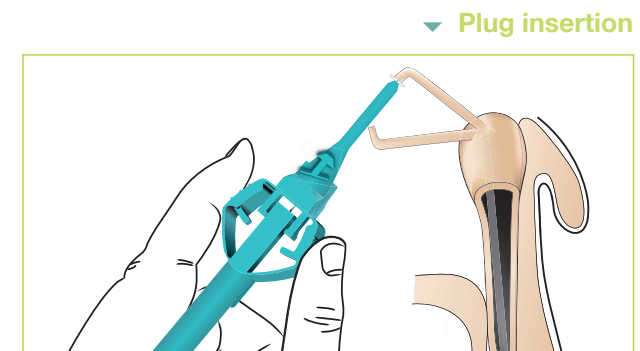
◀ After removal of the metallic guide

REMOVAL

- The plug must be firmly held in contact with the punctum during the removal of the metallic guide.
- Make sure to pull the probe along the main axis of the lacrimal duct.
- Remove the metallic guide.

END OF REMOVAL

The plug must be seated in the punctum with the help of a punctum dilator. Once the plug is in place, the collar should rest flat against the eyelid margin.



▼ Plug insertion

